

Gynaecological Pathology Reporting

Cervical Pathology

Dr Raji Ganesan
Birmingham



By your side

Format

- Introduction
- Cervical biopsy
- Difficulties in diagnosis of CIN
- p16
- Cervical loop
- Squamous carcinoma – diagnosing and staging
- Hysterectomy for squamous carcinoma
- Glandular neoplasia
- Delegate questions

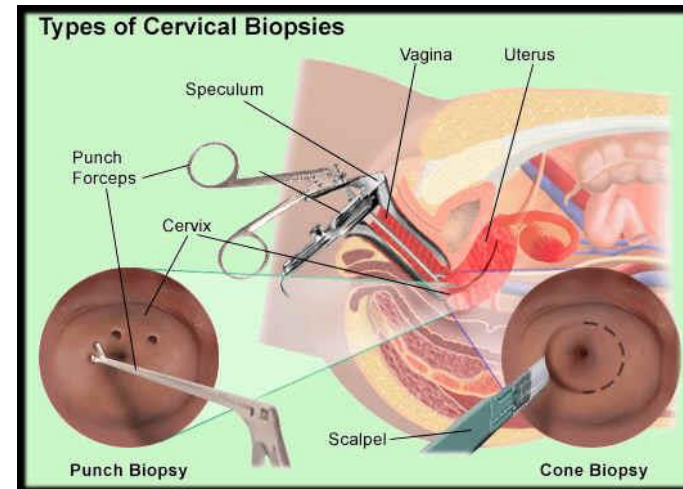


Surgical pathology reporting

- **Purpose:** diagnosis of disease so that the clinician can make a management decision
- **Emphasis:** On bottom line diagnosis
- **Pressure:** On time but accuracy is critical
- Reports generally created by a single pathologist hence little time for reflection or peer review
- Importance of clear, concise, unambiguous reports

Reporting cervical pathology – the punch biopsy

- What are the diagnoses that affect clinical management?
 - CIN3, CGIN, SMILE, invasion
 - Diagnosis of CIN2
 - If a diagnosis of CIN2 is made the patient may be offered ablative treatment.
 - If a diagnosis of CIN2+ is made the patient is likely to be offered excisional treatment.



CIN2 – a difficult diagnosis!



Birmingham Women's
and Children's
NHS Foundation Trust

15 laboratories across New Mexico

Nearly 40000 biopsies

Categorised as

CIN1 to include CIN1, HPV, koilocytosis

CIN2 to include CIN1 -2, CIN2

CIN2 – 3 to include CIN2 – 3 and HSIL

not specified

CIN3

Am J Clin Pathol. 2013 March ; 139(3): 330–335. doi:10.1309/AJCP3D3ZXJXP7NNB.

Cervical Histopathology Variability Among Laboratories:

A Population-Based Statewide Investigation

Julia C. Gage, PhD, MPH¹, Mark Schiffman, MD, MPH¹, William C. Hunt, MA², Nancy Joste, MD², Arpita Ghosh, PhD¹, Nicolas Wentzensen, MD, PhD¹, and Cosette M. Wheeler, PhD²
for The New Mexico HPV Pap Registry Steering Committee

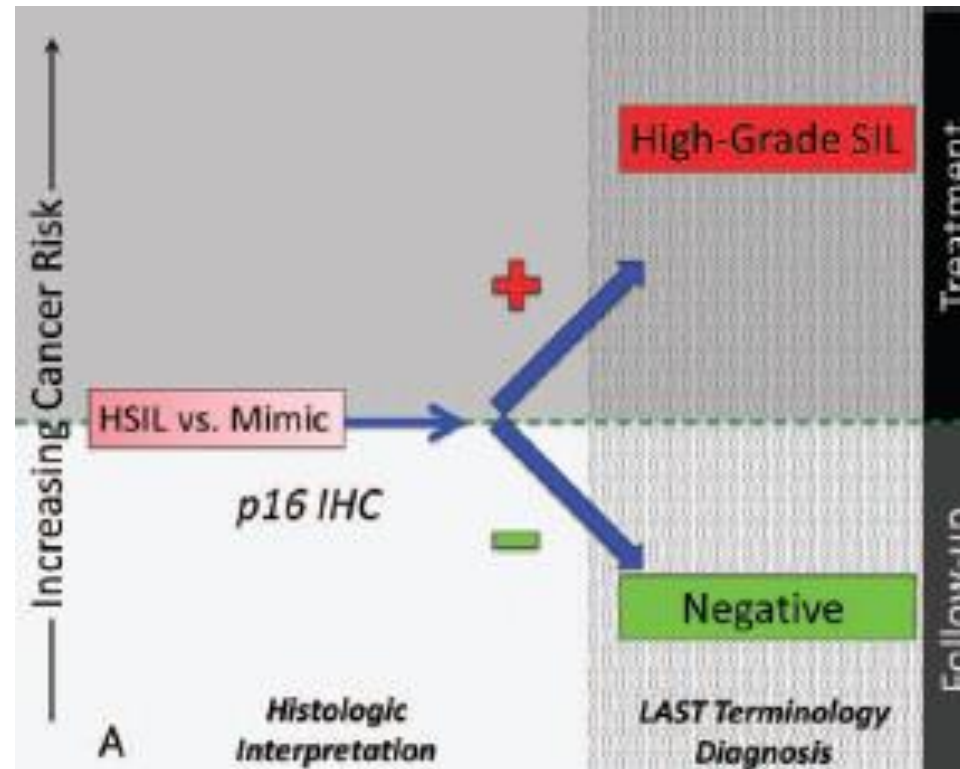
Cytology and age taken into account

p16 use not assessed

CIN2 varied from 7.2 to 22.3% (one outlier at 1.5%)

Use of p16 in non invasive cervical pathology

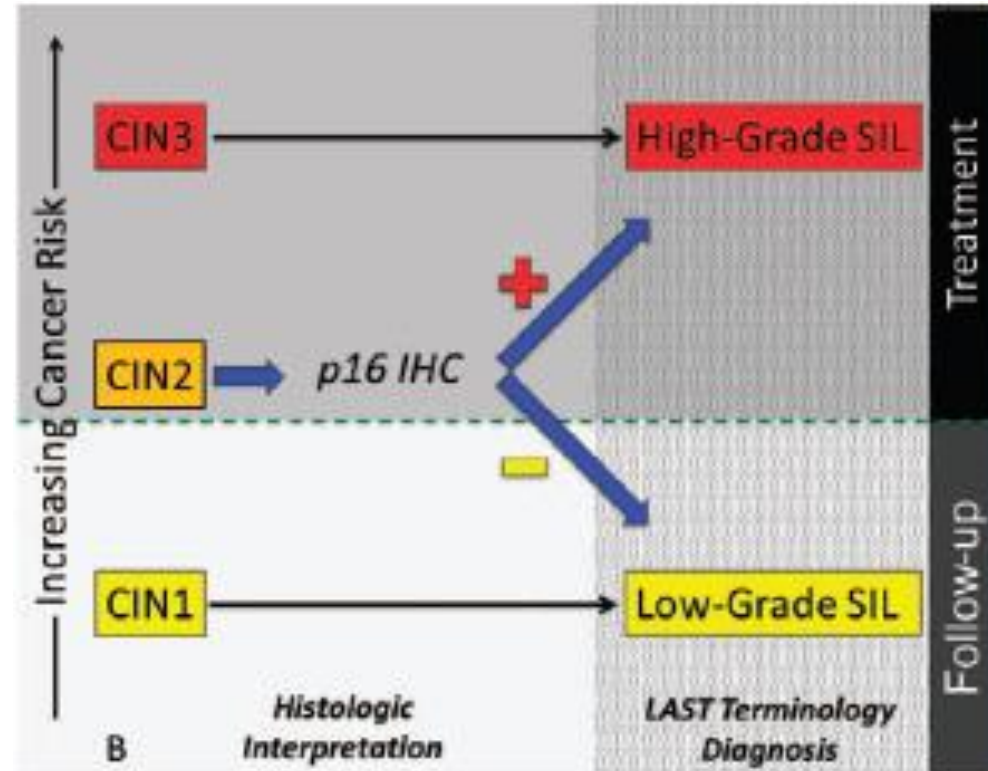
- p16 recommended to differentiate between CIN 2/3 and immature squamous metaplasia/atrophy/reparative changes



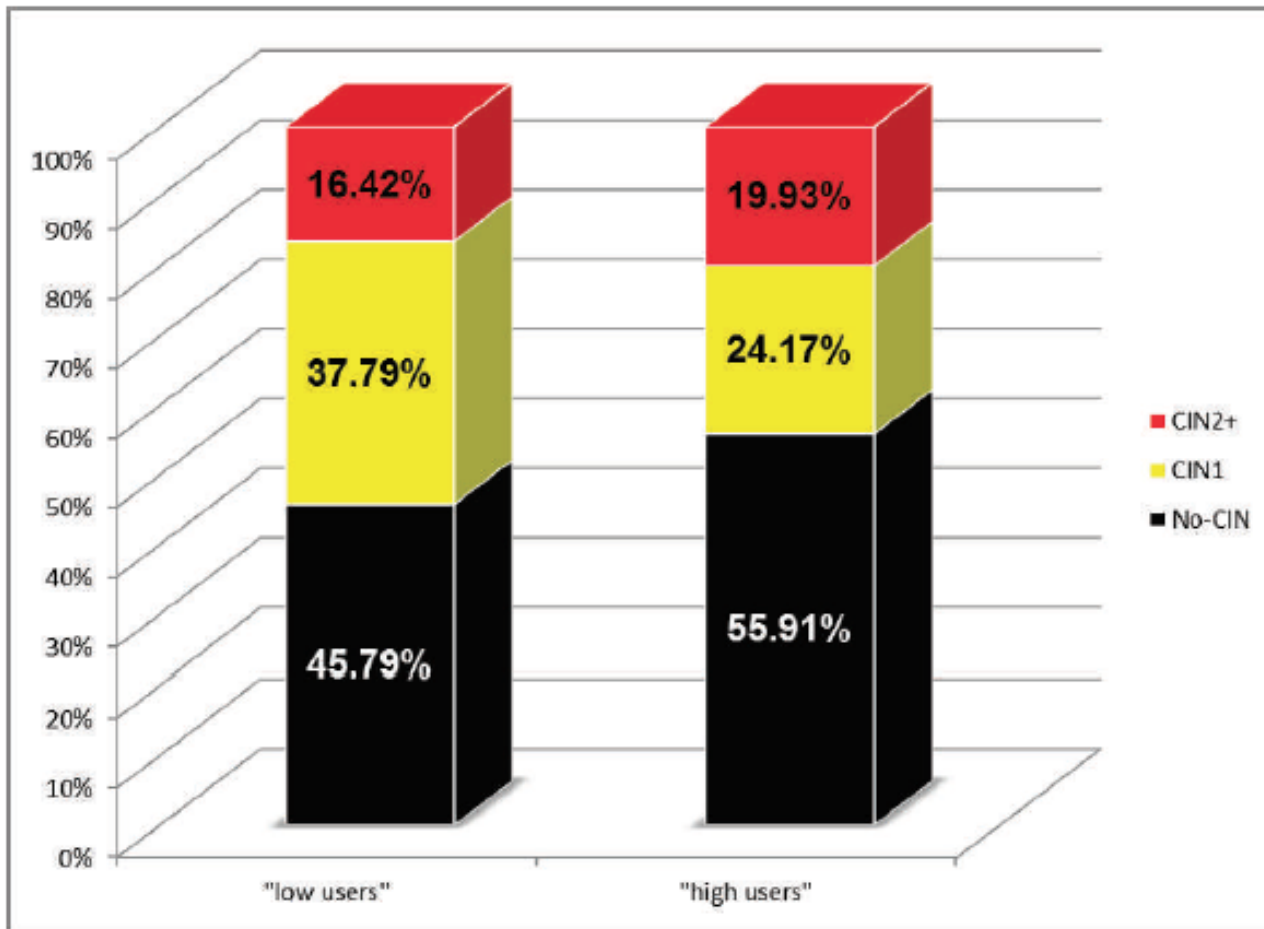
**The Lower Anogenital Squamous Terminology
Standardization Project for HPV-Associated Lesions:**

Use of p16 in non invasive cervical pathology

- To clarify a diagnosis of CIN2
- Block positive favours high grade CIN
- Non block or negative staining favours low grade or non-HPV associated pathology



**The Lower Anogenital Squamous Terminology
Standardization Project for HPV-Associated Lesions:**



Variability of Pathologists' Utilization of p16 and Ki-67 Immunostaining in the Diagnosis of Cervical Biopsies in Routine Pathology Practice and Its Impact on the Frequencies of Cervical Intraepithelial Neoplasia Diagnoses and Cytohistologic Correlations

Charanjeet Singh, MD; J. Carlos Manivel, MD; Alexander M. Truskinovsky, MD; Kay Savik, MS; Samy Amirouche, CT(ASCP); Jana Holler, CT(ASCP); Bharat Thyagarajan, MD; H. Evin Gulbahce, MD; Stefan E. Pambuccian, MD

What if p16 does not correlate with my morphological impression?

What if p16 positive, HPV test negative?

Initial biopsy p16	LEEP diagnosis
diffuse block p16 positive (28 - 66.7%)	CIN2 and CIN3 (HSIL)
negative p16 (7 - 16.7%)	Benign or CIN1
focal/patchy p16 (7 - 16.7%)	CIN2 – 4 (HSIL) CIN1 - 3

Original Article

p16 Immunohistochemistry is Useful in Confirming High-grade Squamous Intraepithelial Lesions (HSIL) in Women With Negative HPV Testing

Other situations where I have found p16 useful

- Diagnosis of CTZ
- Unexpected CIN
- Tubo-endometrioid metaplasia
- Ciliated CGIN

Reporting cervical pathology – the biopsy

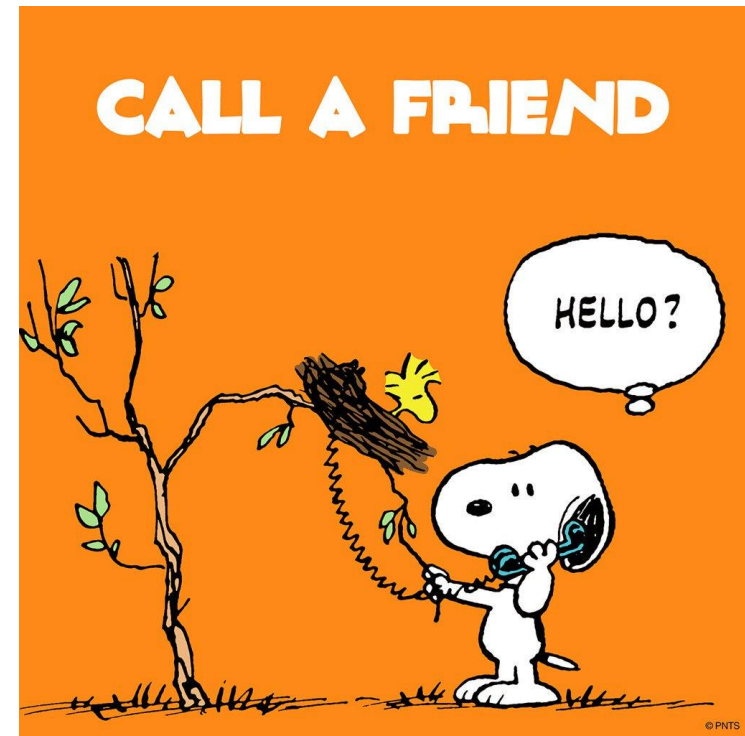- How many levels?
 - 3 levels recommended by the tissue pathway document.
 - If there is little squamous epithelium, disrupted surface, cross-cutting, non correlation, I would do an additional 3 levels
- When p16?
 - p16 recommended to differentiate between CIN 2/3 and immature squamous metaplasia/atrophy/reparative changes

The cervical biopsy

- When do I call a biopsy inadequate?
 - rare
 - when there is no transformation zone sampling, unless specifically mentioned as directed biopsy
 - when the sample is disrupted or crushed or very small
 - when there is no glandular tissue in context of cytology diagnosis of glandular dysk

The cervical biopsy

- When do I call a friend?
 - regular multiheaders – discrepancy with cytology, previous biopsy or colposcopy
 - a diagnosis of CIN2
 - interpretation of p16



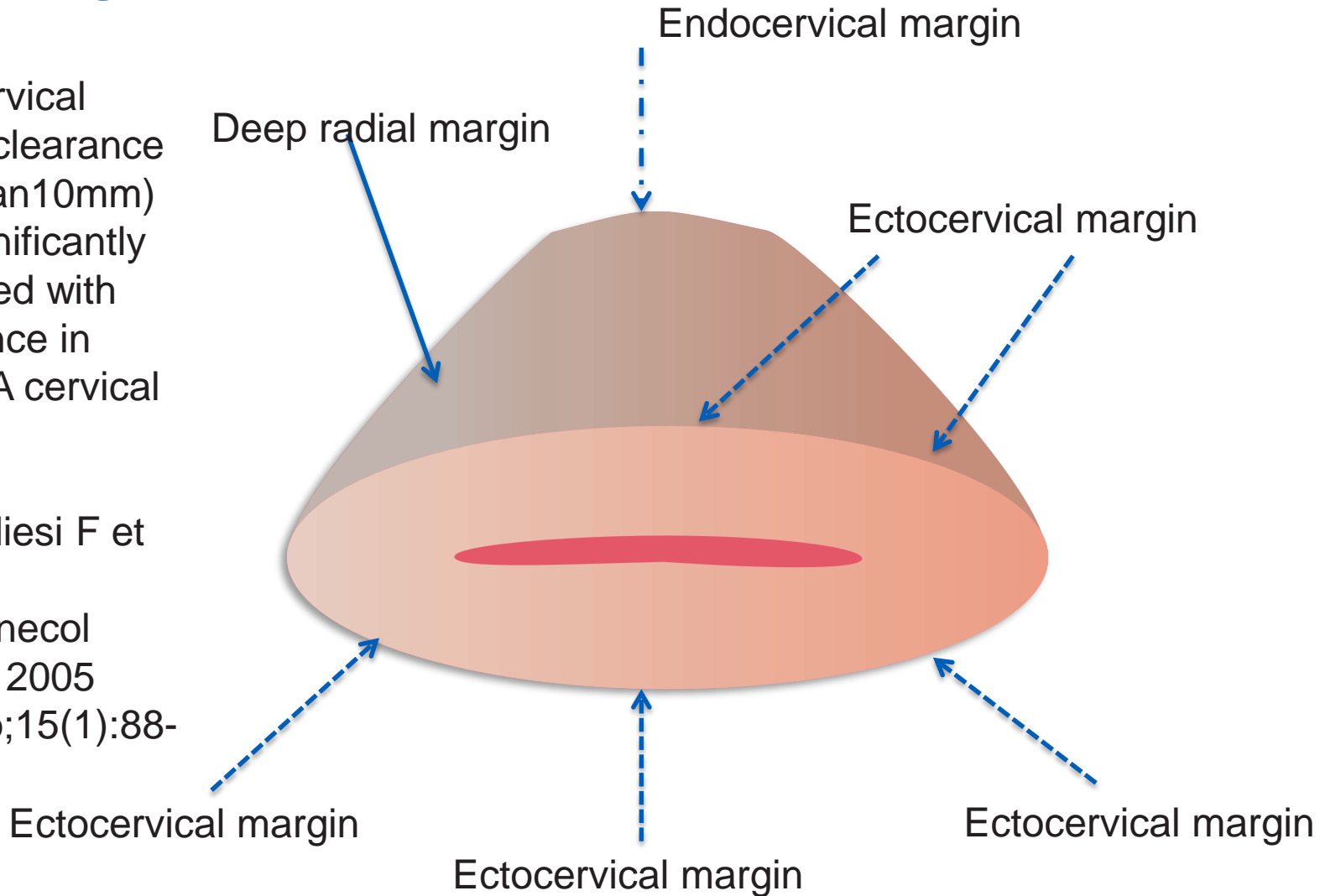
Reporting cervical pathology - the loop

- Trimming a loop
- Painting
- Turning over the end block
- Multiple slices in one block
- More than one piece - don't fret. Identify the epithelial surface and cut parallels
- Top hat - don't fret - identify convexo concave surface.

Understanding the margins

Endocervical margin clearance (less than 10mm) was significantly correlated with recurrence in stage 1A cervical cancers

Raspagliesi F et al
Int J Gynecol Cancer. 2005
Jan-Feb;15(1):88-93.



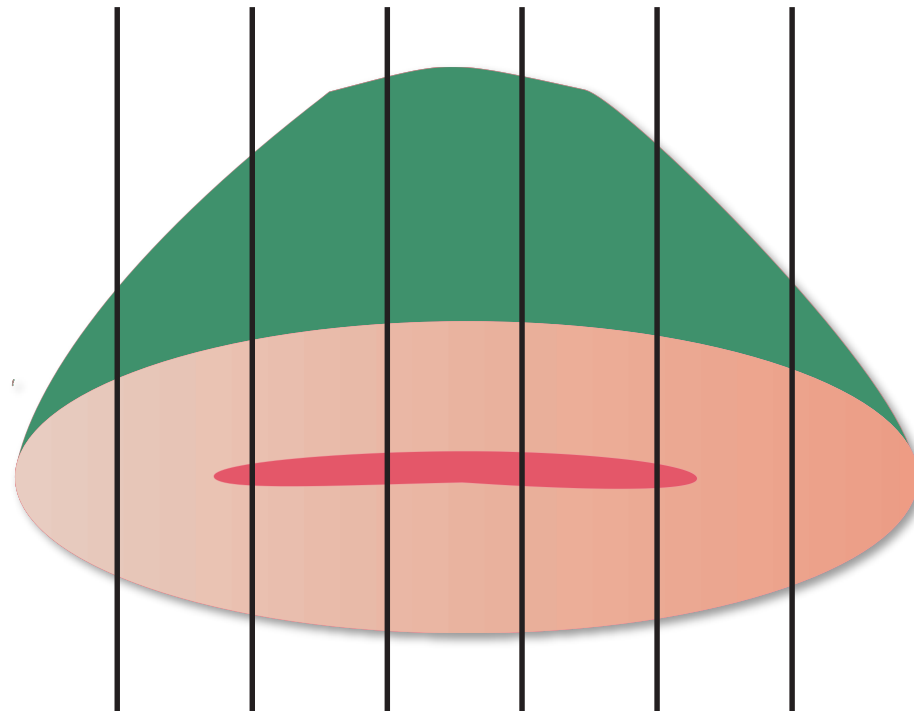
Ink the resection margins

Slice serially perpendicular to OS

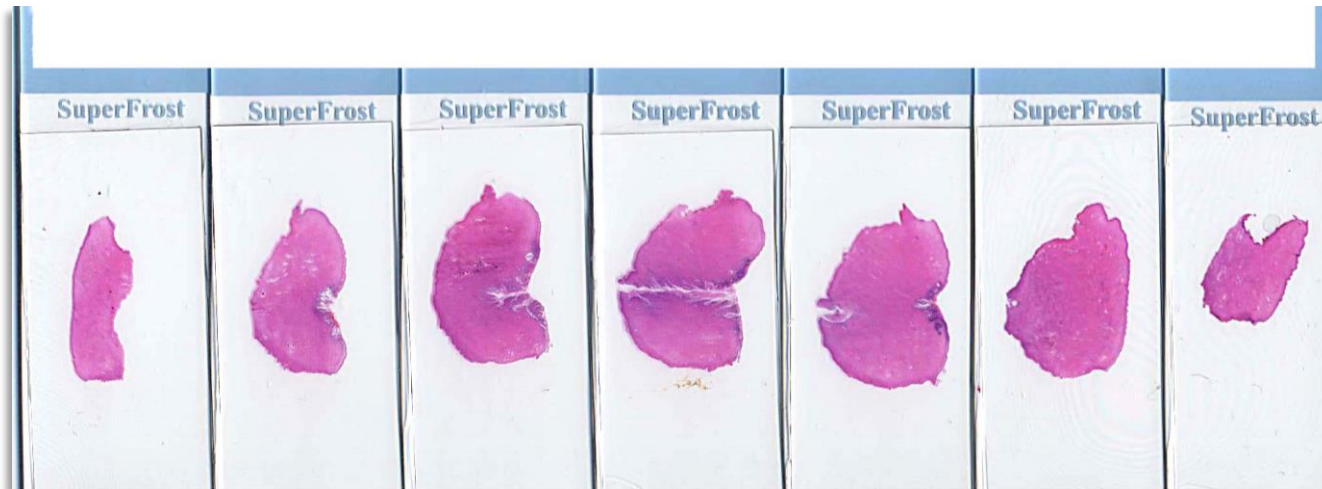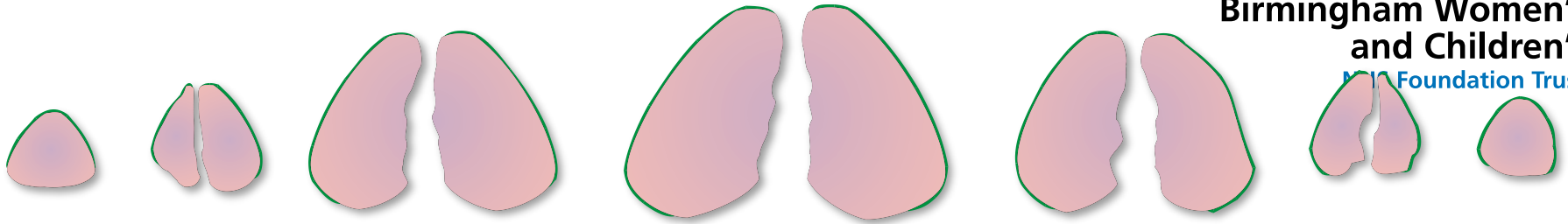
Don't put
epithelial
surface on
bench

Slices 2.5 to
3mm apart

One slice per
cassette



Slicing the loop or cone biopsy



Crescendo – decrescendo slice pattern

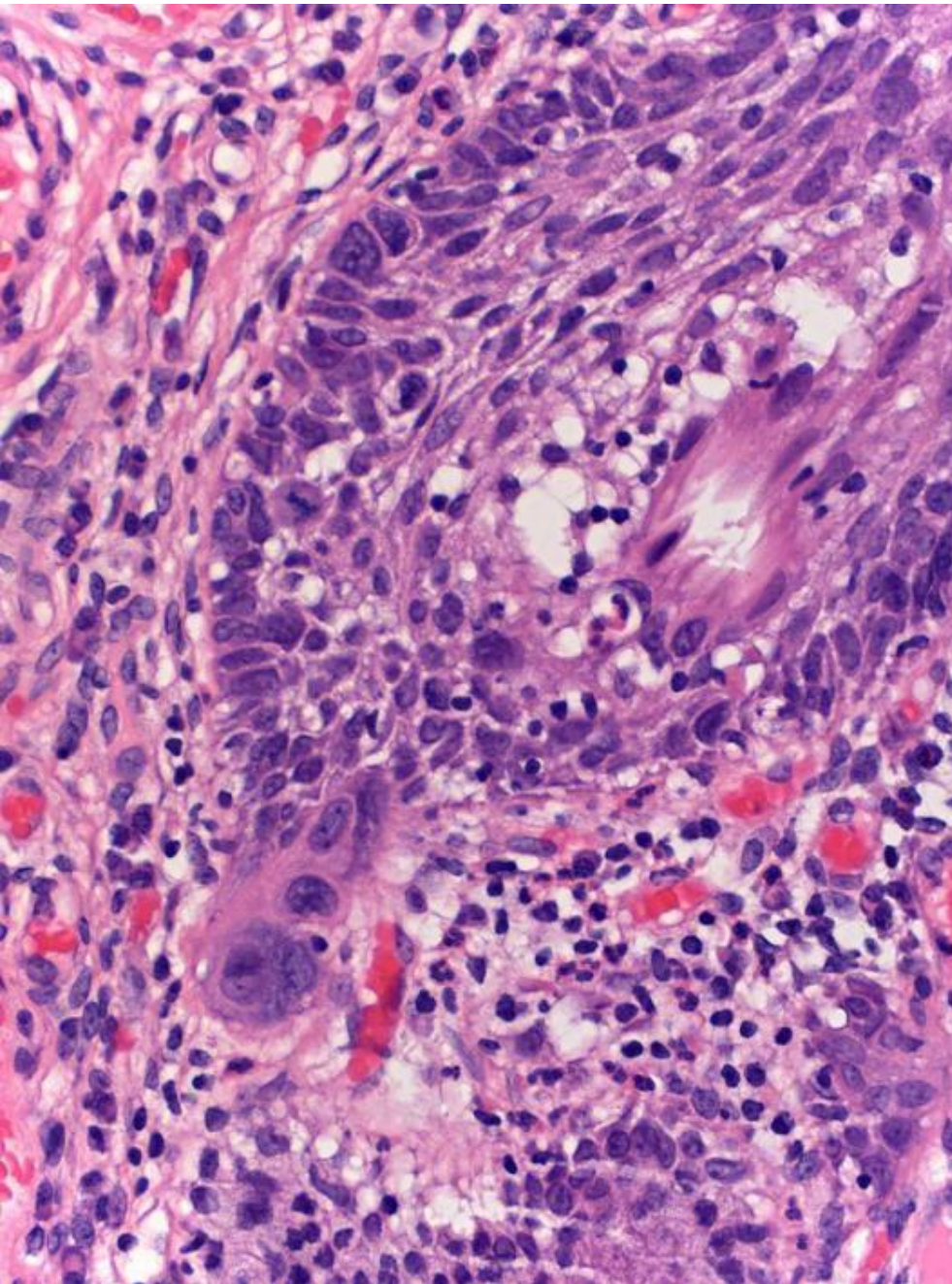
Thanks to Dr Lynn Hirschowitz

Reporting cervical pathology – the loop

- The variations:
 - Loop in multiple pieces – identify the epithelial surface
 - Top hat – try and identify the concavo-convex surface
- Levels:
 - One deep level to see ‘full face’ of slice
 - Levels to see margin involvement or routine levels in all cases to rule out invasion – no role

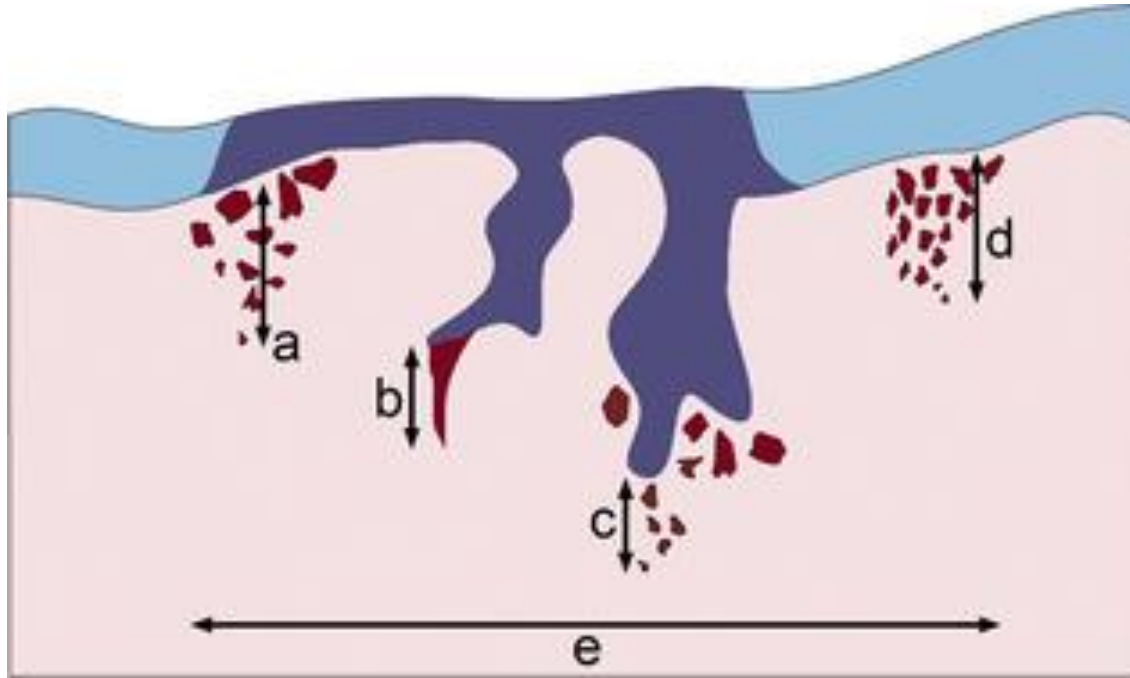
Cervical pathology reporting – the loop

- What matters clinically?
 - Whether there is invasion or not.
 - What is the stage? Unifocal vs multifocal?
 - For audit and governance
 - Grade of CIN
 - Correlation with cytology or previous biopsy and/or colposcopy findings
- For audit and governance
 - Grade of CIN
 - Correlation with cytology or previous biopsy and/or colposcopy findings
- Features suggesting that there may be invasion
 - Involvement of crypts by expansile CIN3 and luminal necrosis
 - Large volume of CIN3



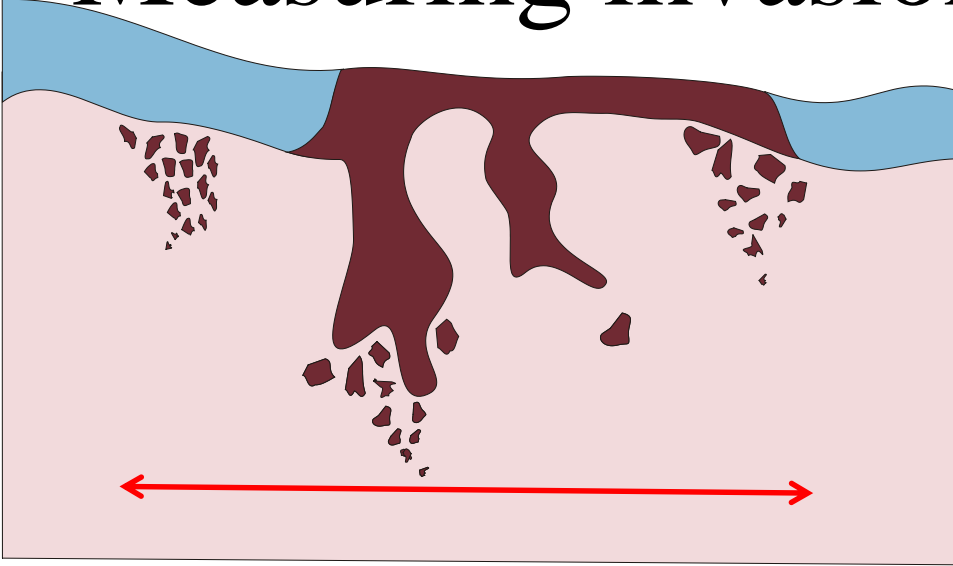
- Hypermaturation and eosinophilia of basal epithelial cells
- Loss of basement membrane
- Loss of basal palisade
- Angulated buds
- Stromal reaction

Measuring invasion - depth

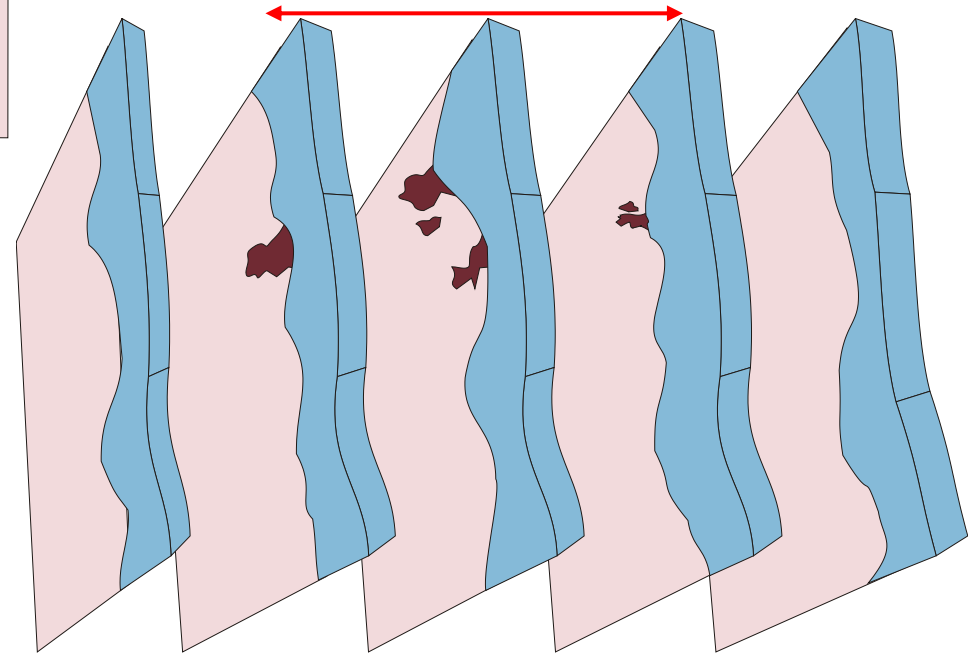


Measure from the base of the epithelium (surface or glandular) from which the carcinoma arises. If there is no obvious epithelial origin measure from the tumour base (deepest focus of tumour invasion) to the base of the nearest surface epithelium.

Measuring invasion - width



The maximum horizontal dimension/width of tumour is measured in the section in which the width is greatest (from the edge at which invasion is first seen, to the most distant edge at which invasion is identified).



The 'third' dimension

Staging – do not use the term microinvasive – means different things to different groups



- FIGO does not include the term ‘microinvasive’ carcinoma
- Term ‘microinvasive’
 - in UK = FIGO stage IA1 +/- IA2 disease
 - in USA = stage IA1 disease
- American SGO defines tumours with LVI and dimensions of FIGO stage IA tumours = FIGO stage IB
- RCPATH dataset has discouraged the term ‘microinvasive carcinoma’ and for using the specific FIGO stage as a descriptor

FIGO Stage allocation

- Multifocal vs unifocal carcinomas
- RCPATH guidance
- ICCR guidance
- Evidence

Multifocal FIGO Stage 1A1 Cervical Squamous
Carcinomas have an Extremely Good Prognosis
Equivalent to Unifocal Lesions

Evidence

Patrick Mellwaine, M.D., Hans Nagar, F.R.C.O.G., and W. Glenn McCluggage, F.R.C.P.A.

- 208 cases of squamous carcinoma on LLETZ or cone
- 104 stages as FIGO 1A1
- 26 – more than one focus of invasion (4 not included)
- 21/22 – repeat LLETZ or cone due to margin involvement by CIN or carcinoma – none (9 to 91 month follow up) has had abnormal cytology or tumour recurrence
- 11/21 could have been classed as 1B1
- Recommended – if greater than 2mm between foci - multifocal

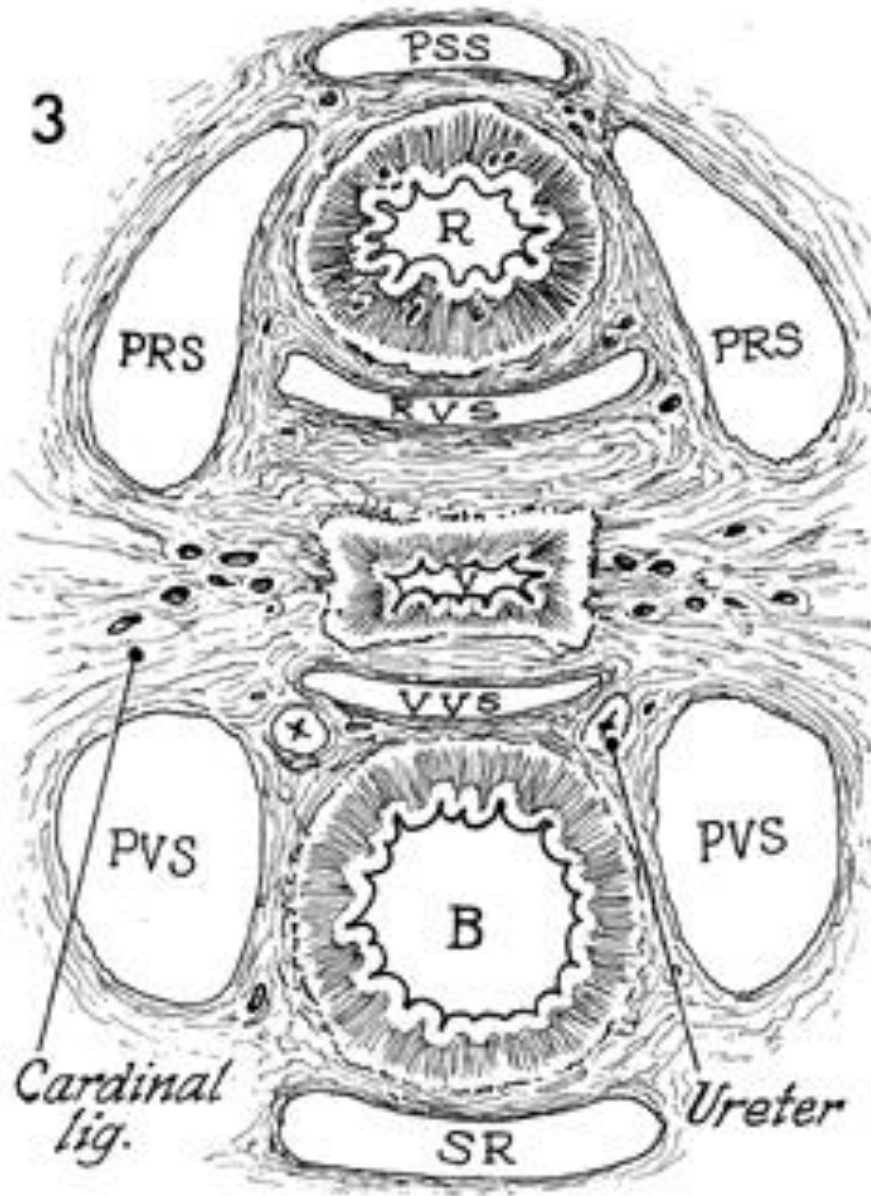
Other guidance regarding measurements

- At trachelectomy or hysterectomy final measurements should include the previous specimens
- Maximum depth = greatest depth in the specimens
- Maximum horizontal dimension = add together the horizontal dimensions – maybe an overestimate.

Reporting cervical pathology – the hysterectomy

- Trimming – guidance RCPATH and ICCR
- Special consideration – the hysterectomy after multiple loops, hysterectomy after chemoradiotherapy, the paracervical tissue.
- Important to record – depth of invasion of cervical stroma (inner, middle or outer third), Ivsi – both predict recurrence but do not affect survival.

3



The presacral space (*PSS*) is at the top of the rectum (*R*) and the pararectal spaces (*PRS*).

The rectovaginal space (*RVS*) is between the rectum and vagina (*V*).

The vesicovaginal space (*VVS*) is between the bladder (*B*) anteriorly and the vagina (*V*).

The paravesical space (*PVS*) is between the bladder (*B*) anteriorly and the pararectal space (*PRS*).

Between the pararectal space and the paravesical space is the lateral extent of the cardinal ligament, originally described as the "web" by Wertheim.

The web contains the venous network of the internal iliac vein.


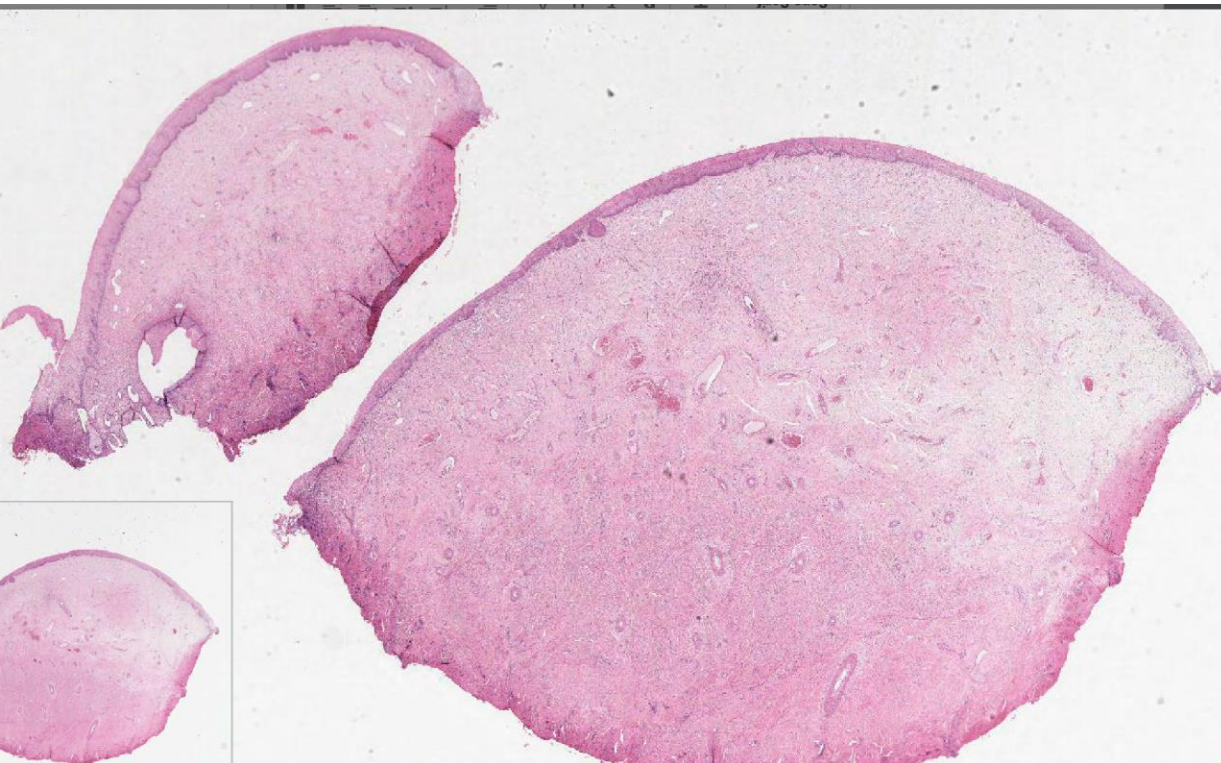
Anterior to the bladder is the space of Retzius (*SR*), the retropubic space.

Delegate questions

- Should we treat 'cannot exclude stage 1B1' cervical cancers, for very small tumours, but seen in 3-4 consecutive slices, more conservatively than 'proper 1B1' tumours (clearly >7mm across on glass slides)?
- The clinicians are aware of this and hopefully the new BGCS guidelines and the SHAPE trial will address this issue
- WRT - 'cannot exclude stage 1B1' – I find this unhelpful. I strongly recommend the use of available guidelines, consistence within your clinical group, clearly explain the reasoning behind your staging in your report and at MDT. Sometimes I might state 'final staging after MDT discussion'

Delegate questions

- I sometimes find it difficult to definitively identify the endocervical margin in a LLETZ specimen. What tips do you have for this?

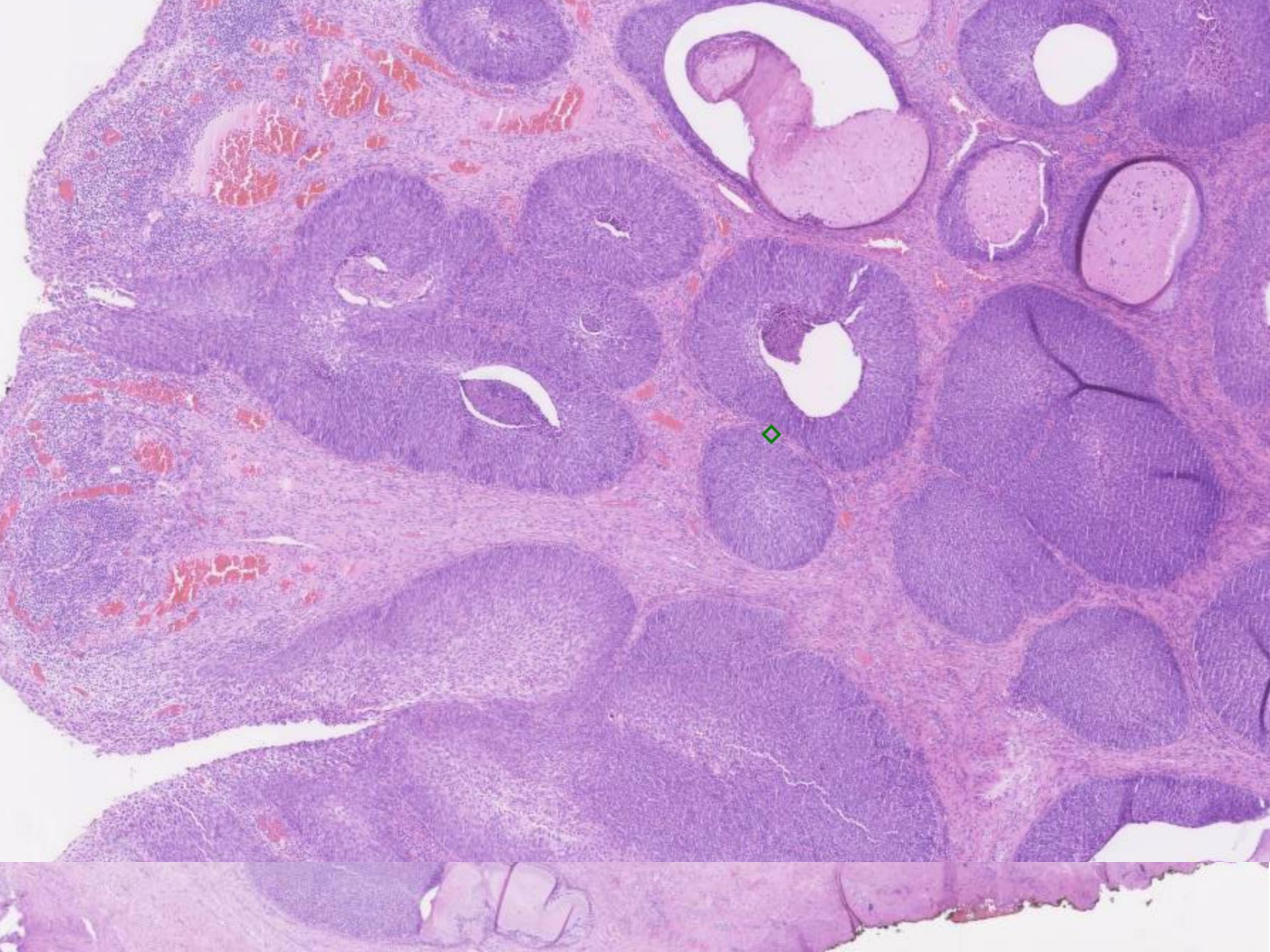


Delegate questions


- and why is an involved endocervical margin treated differently to an involved ectocervical margin?
- I am assuming that the involvement is by CIN or CGIN. Irrespective of whether it goes to the margin, CIN is followed up by TOC.
- CGIN is followed up by TOC only when completely excised.
- Follow up of Stage 1A1 – if CIN goes to the margins and carcinoma completely excised – re-excise
- Follow up completely excised Stage 1A1 – cytology at 6, 12 and annual x 9 years – return to normal
- Follow up completely excised Stage 1A2 and conservatively treated 1B1 – management by gynae onc.

Delegate questions

- Reporting of cervical punch biopsies. On the proforma there is a heading 'Extension into crypts' I struggle with this as sometimes the epithelium seem thick and may extend into crypts but as a crypt is not seen clearly the distinction is hard to make. So my question is when is there extension into crypts on a cervical punch biopsy and what are the criteria for it?
- Not aware of proforma for biopsies. Extension into crypts is an item on loop reporting proforma. Reason explained earlier.



Delegate questions

- LLETZ specimens and CIN extending to margins. How much should we chase margin status? Should we turn end blocks over?
- Not my practice. If the trimming is consistent (audit ) then usually not a problem
- How close is too close?
- CIN to margin not measured routinely
- What matters clinically?
- With CIN – excised or not excised
- My impression is that cases with early stage cancer get a repeat LLETZ if the CIN is not excised. Otherwise, it's usually a 'test of cure' only at next follow up.
- Yes

Delegate questions

- Creeping CGIN: What is its definition and differential diagnosis?
- Not a term that I recognise but could be used if CGIN is extending beyond the cervix

Delegate questions

- In intestinal type cervical adenocarcinoma, do you see floating mitoses and/or apoptotic bodies just like in usual type of cervical adenocarcinoma and if you see them, does it mean almost certainly primary cervical rather than met from colo-rectum?
- Very rare but significant differential diagnosis. Usually metastasis from colorectal primary will show dirty necrosis. 'Clean' apoptosis commoner with cervical primary. Immunos very distinctive and useful